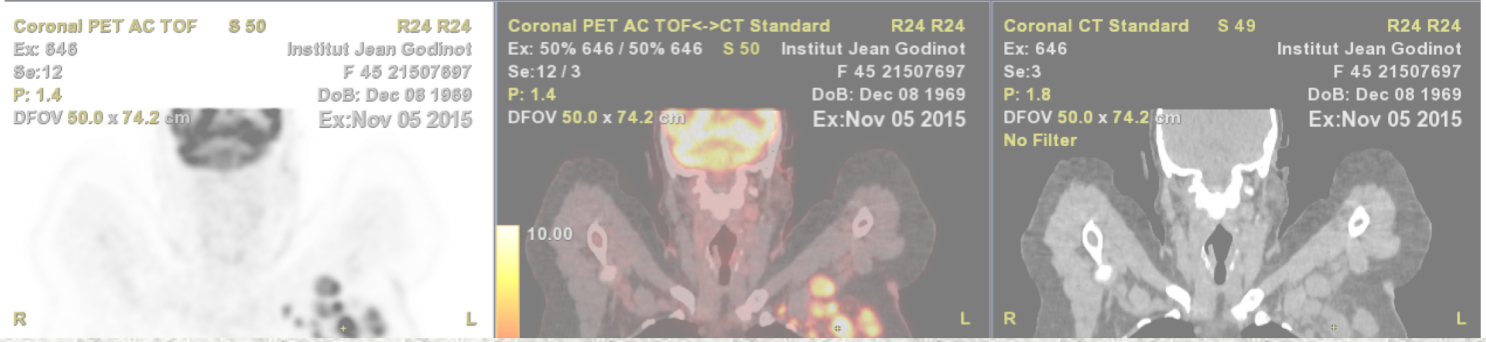


# Segmentation of Axillary and Supraclavicular Tumoral Lymph Nodes in PET / CT: A Hybrid CNN / Component-Tree Approach

**D. L. Farfan Cabrera, N. Gogin, D. Morland, B. Naegel, D. Papathanassiou, N. Passat**

Université de Reims Champagne Ardenne, CReSTIC, EA 3804, 51097 Reims, France

General Electric Healthcare, Buc, France

Département de Médecine Nucléaire, Institut Godinot, Reims, France

Université de Strasbourg, CNRS, ICube, Strasbourg, France

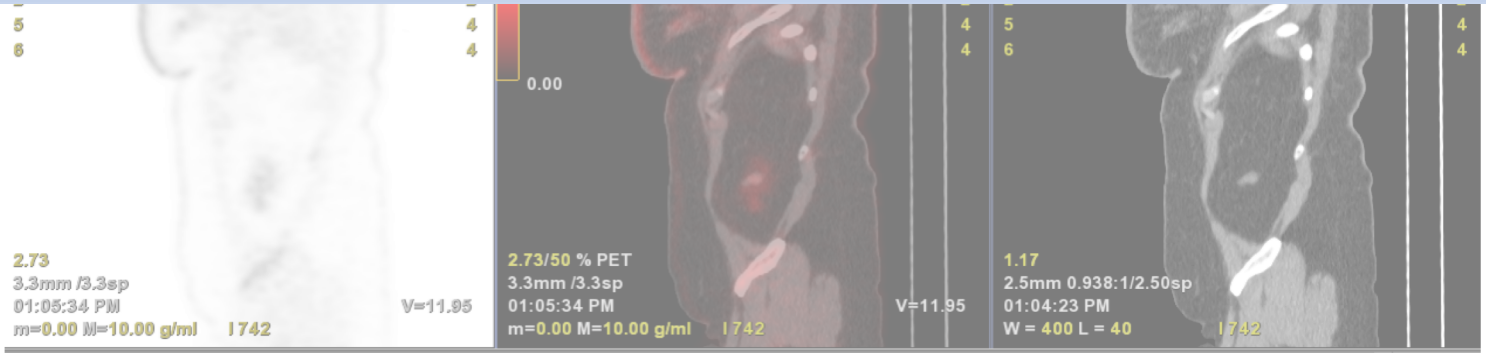

# Automatic axillary lymph node tumor segmentation in PET/CT

## What are lymph nodes?

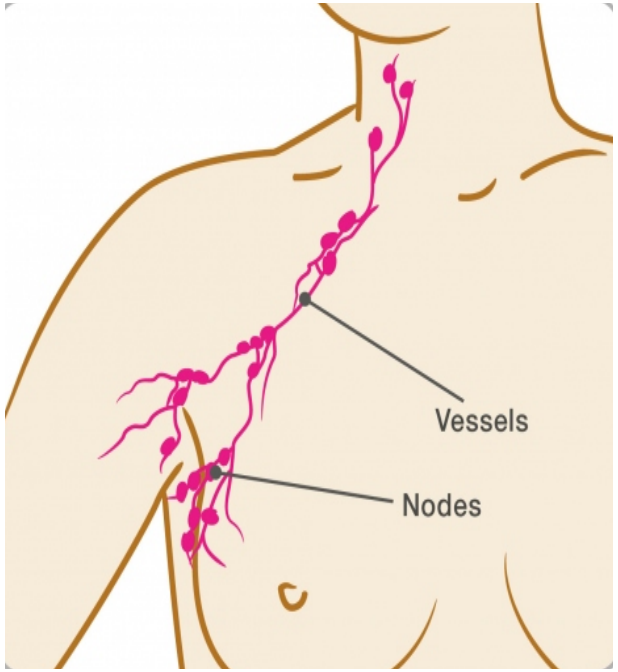


Patient with no breast cancer

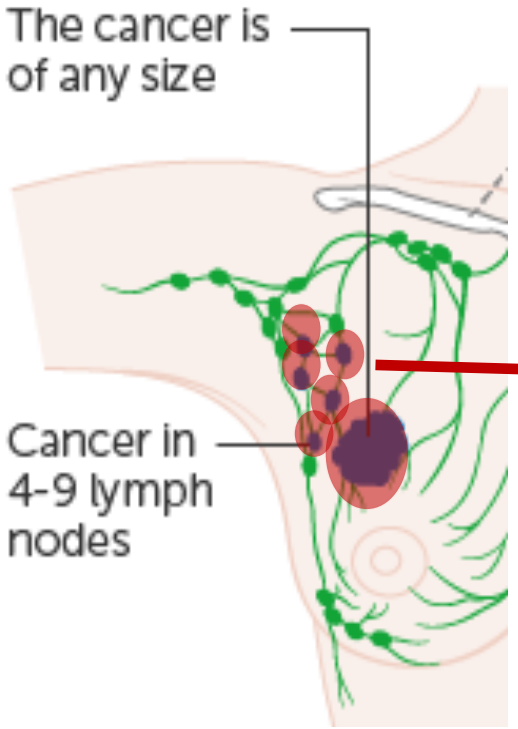


Patient with breast cancer

**lymph nodes are the first organs reached by cancer**

# Automatic axillary lymph node tumor segmentation in PET/CT

## What are our contributions?

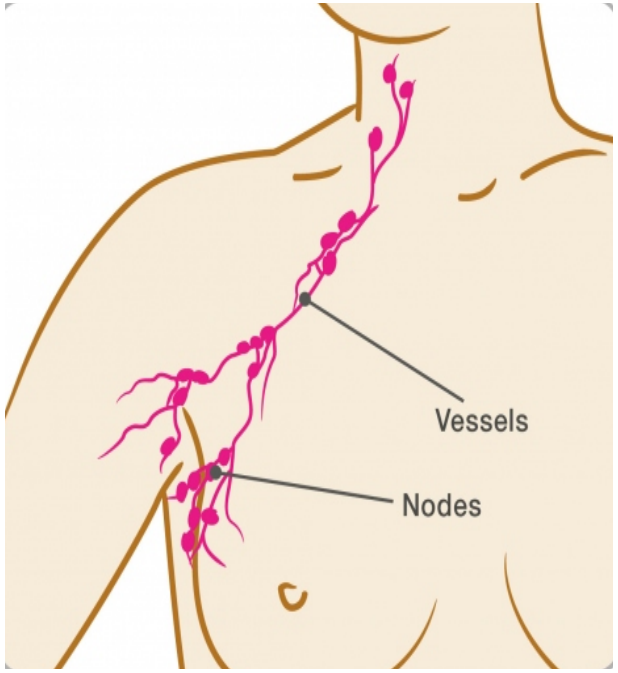


**Patient with no breast cancer**

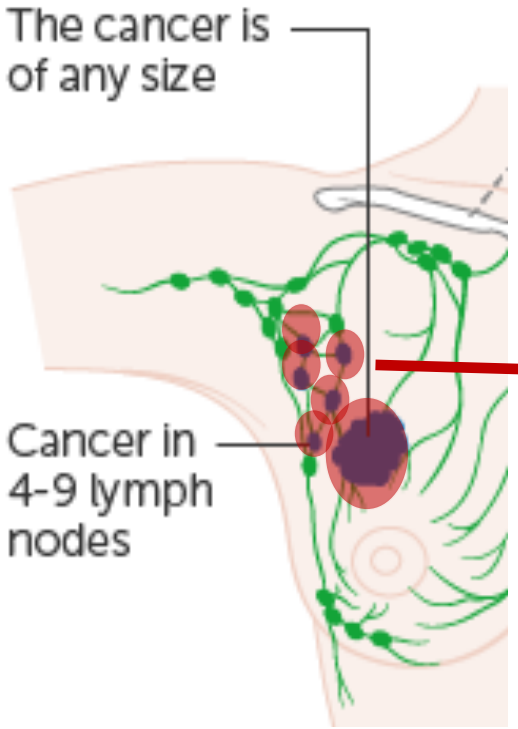


**Patient with breast cancer**

**1st Contribution:**

- Provide a prognostic factor for the staging of breast cancer

**lymph nodes are the first organs reached by cancer**

**Cancer staging is determined by:**
**N: number of lymph nodes with cancer**
**T: tumor volume**
**M: metastasis state**

# Automatic axillary lymph node tumor segmentation in PET/CT

## What are our contributions?

**2nd Contribution:**

- Help doctors to identify quicker false positive coming from brown fat

**PET image**

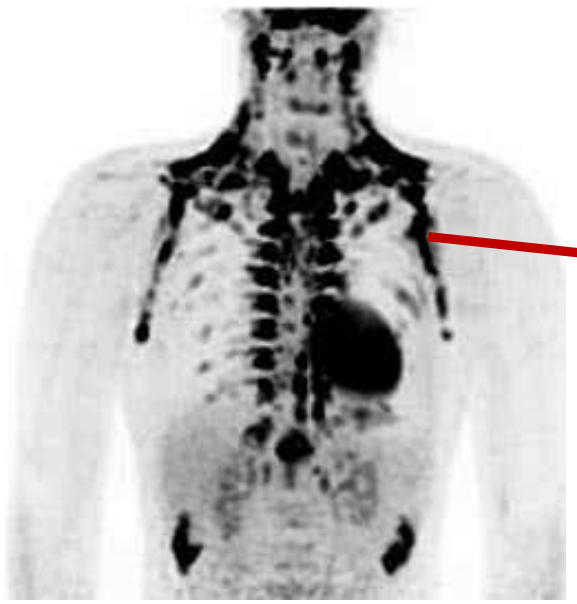

**brown fat**

**PET image**
**Brown fat shows up (due to exposure to cold)**

- Brown fat has the same metabolism as tumor cells
- Brown fat generates **false positives** that can be mistaken by tumors

1. Data preprocessing

2. Component-tree extraction

3. Feature map generator

4. FCNN and component-tree fusion

5. 3D-FNCNN architecture

6. Segmentation results

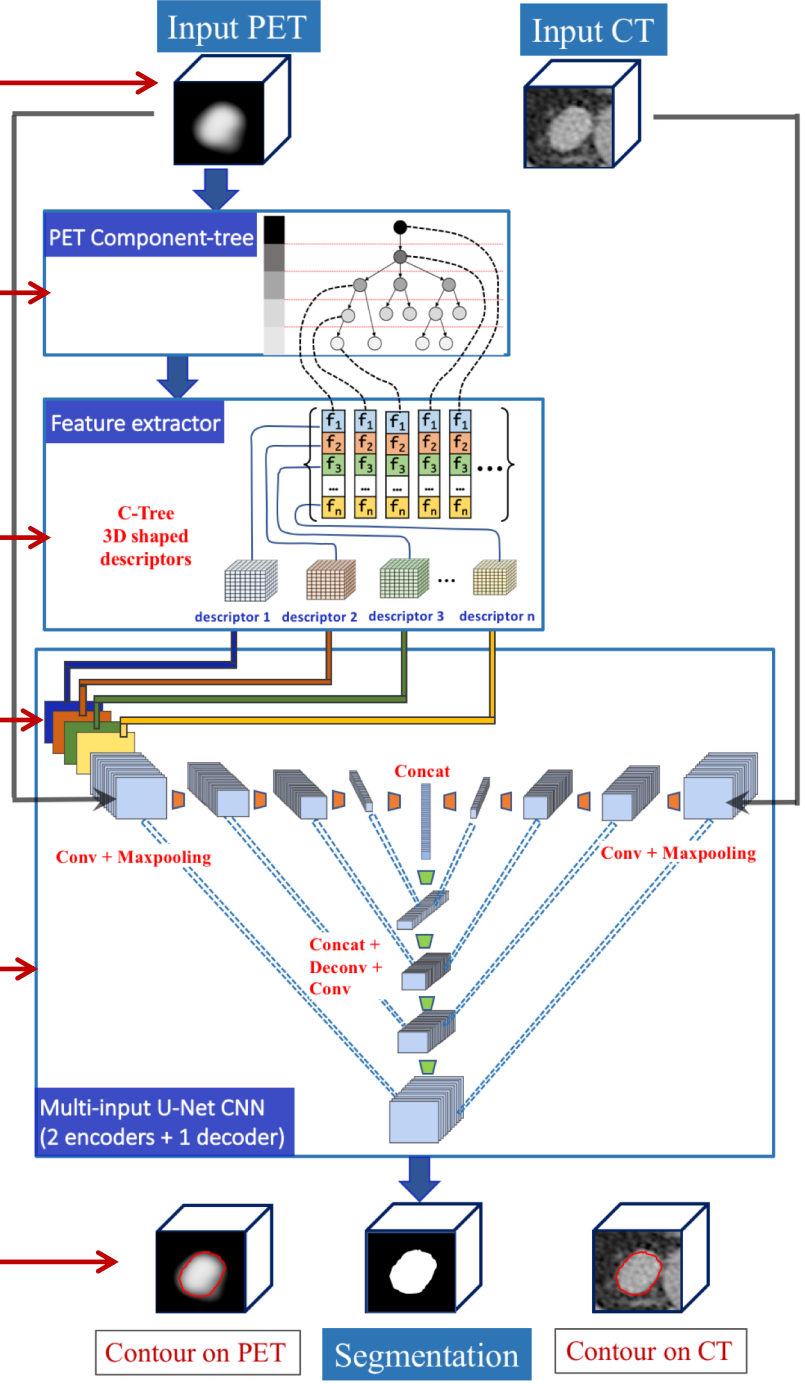

# Automatic lymph node tumor segmentation in PET/CT

## 2. Component-tree extraction

### What is a component-tree?

| | | | | | | |
|---|---|---|---|---|---|---|
| 3 | 3 | 3 | 3 | 3 | 3 | 3 |
| 3 | 2 | 2 | 2 | 2 | 2 | 3 |
| 3 | 2 | 1 | 2 | 4 | 2 | 3 |
| 3 | 2 | 2 | 2 | 2 | 2 | 3 |
| 3 | 3 | 3 | 3 | 3 | 3 | 3 |
| 3 | 0 | 0 | 0 | 3 | 3 | 3 |
| 3 | 3 | 3 | 3 | 3 | 3 | 3 |

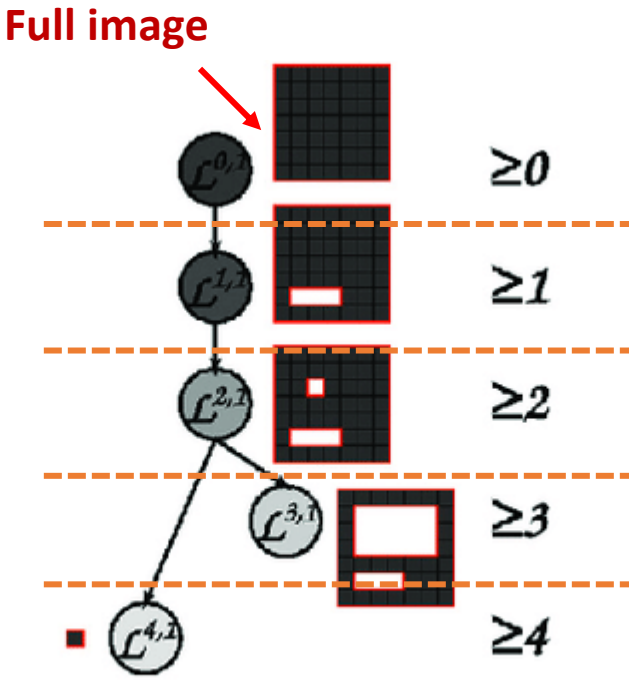


- Each node is a connected component
- Root node contains all the image
- Follows a hierarchical structure according to gray levels
- Each tree level corresponds to a gray level
- Each node belongs to its ascendants nodes

# Automatic lymph node tumor segmentation in PET/CT

## 2. Component-tree extraction

tumors

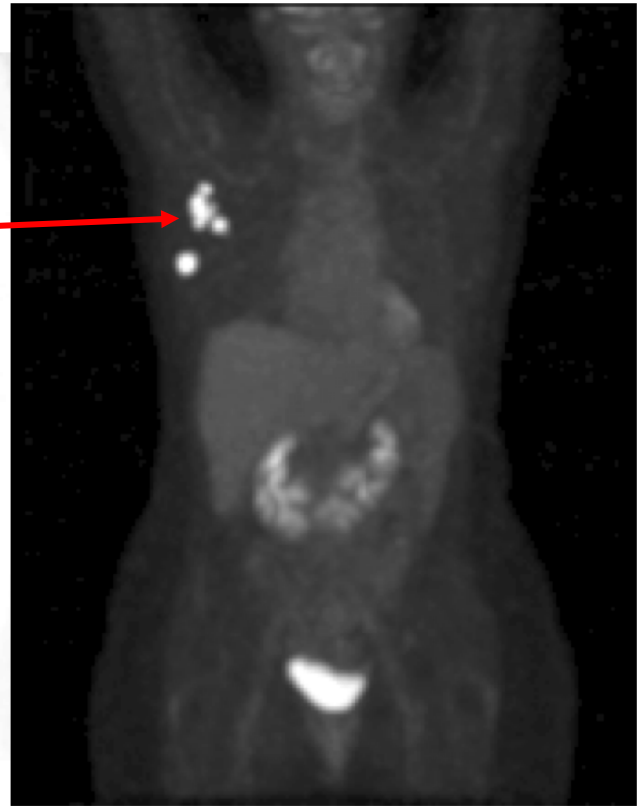

PET image
Coronal MIP view

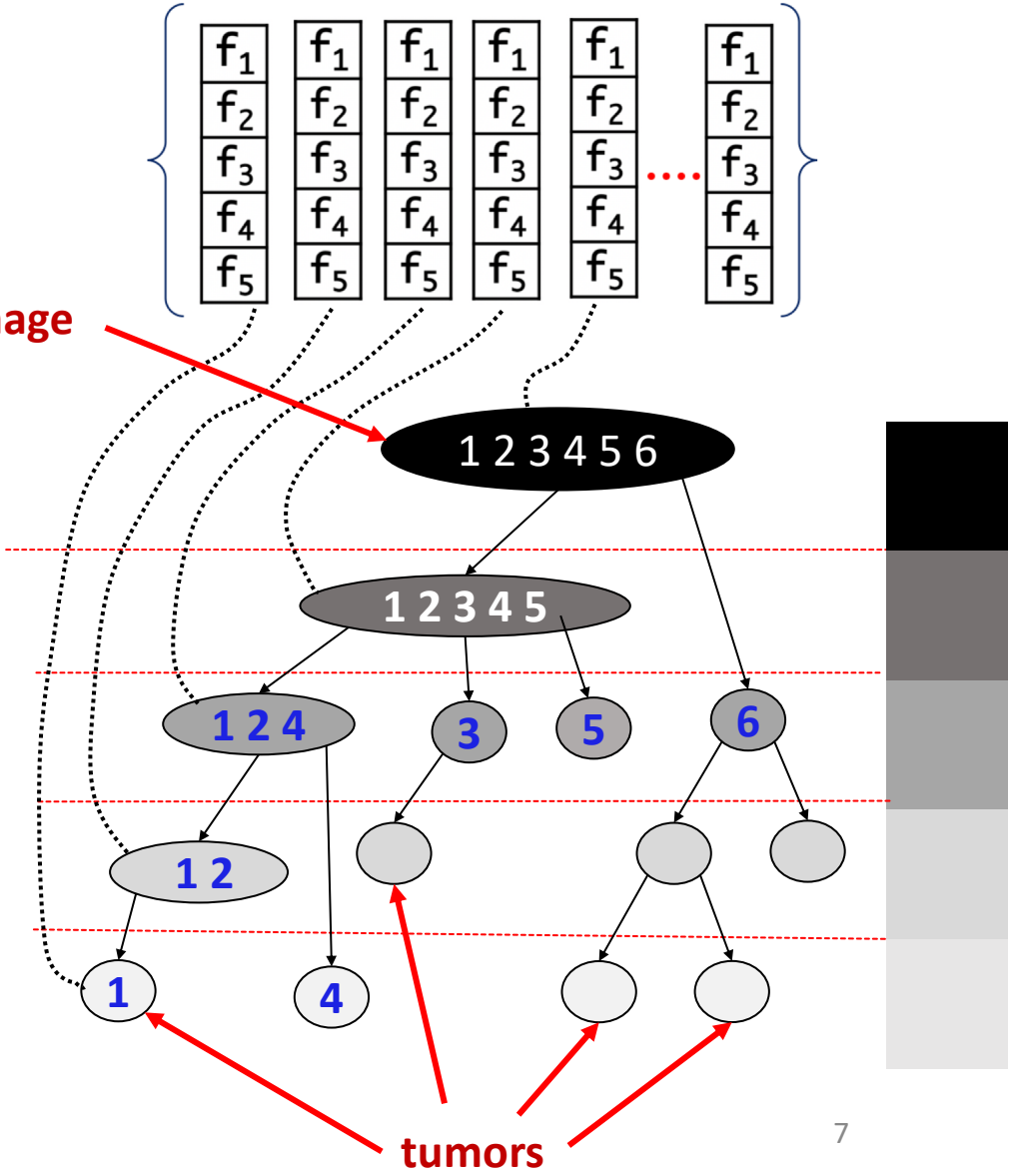

# Automatic lymph node tumor segmentation in PET/CT

## 2. Component-tree extraction

For each node $N_i$, it is computed:

- **f1 → G($N_i$):** mean gradient of node contour in PET
- **f2 → H($N_i$):** mean HU value in CT
- **f3 → S($N_i$):** standard deviation of H
- **f4 → R($N_i$):** relative integral volume
- **f5 → L($N_i$):** position with respect to the lungs

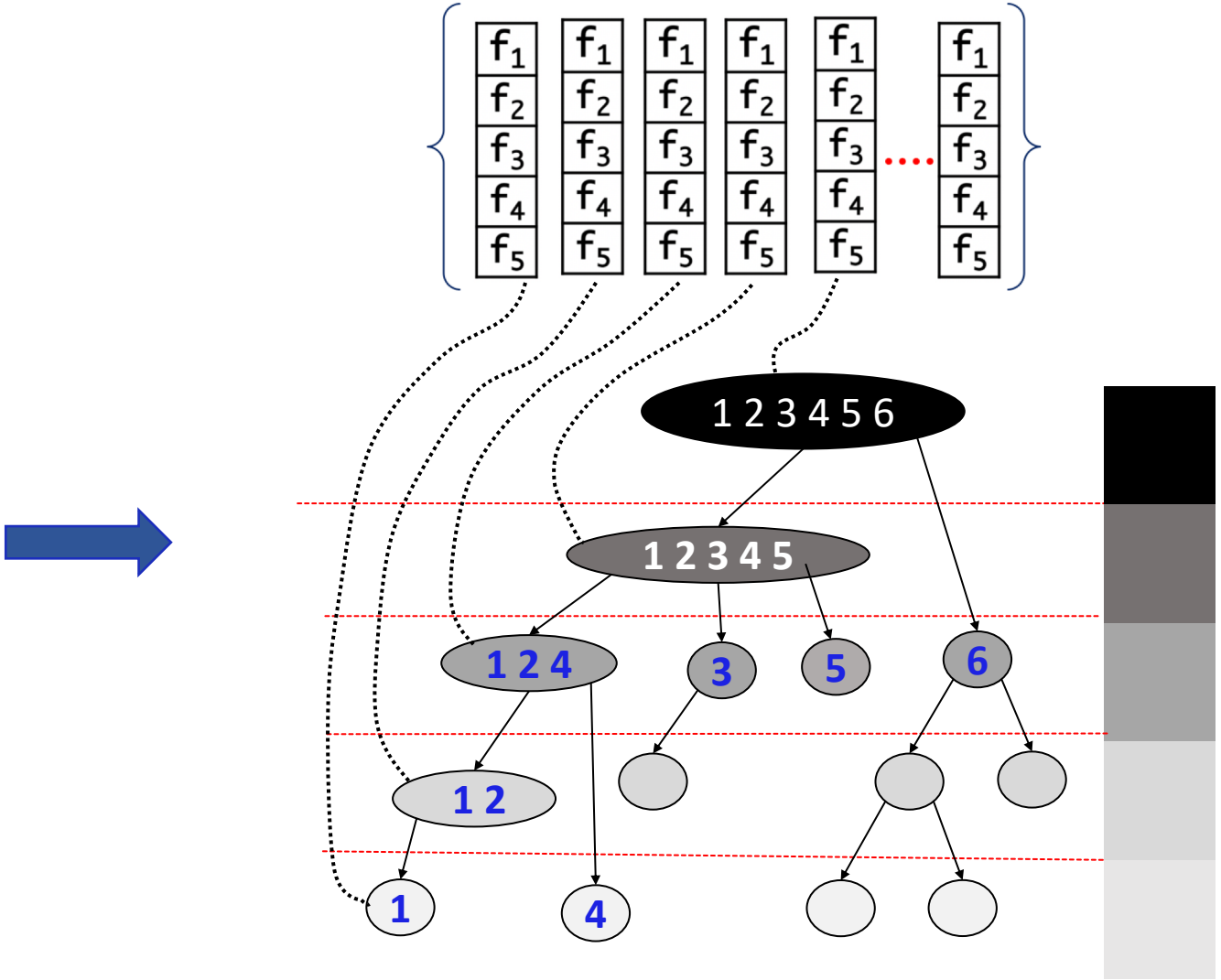

# Automatic lymph node tumor segmentation in PET/CT
## 2. Component-tree extraction

### Goal of these descriptors?

We assign to each **node** 5 descriptors

For each node $N_i$, it is computed:

- **f1 → G($N_i$):** mean gradient of node contour → **lymph node have high contour gradient**
- **f2 → H($N_i$):** mean HU value in CT → **lymph nodes have positive HU value**
  **brown fat has negative HU value**
- **f3 → S($N_i$):** standard deviation of H → **lymph nodes have low standard deviation**
- **f4 → R($N_i$):** relative integral volume → **lymph nodes have high contrast with their neighbourhood**
- **f5 → L($N_i$):** position with respect to the lungs → **lymph nodes are ouside the lungs convexhull**

# Automatic lymph node tumor segmentation in PET/CT

## 3. Feature map generator

### From feature vectors to feature volumes?

We assign to each **voxel** 5 descriptors

For each voxel **x** in the PET image, it is computed:

$$G(x) = \boxed{\max_i} G(N_i)$$ → lymph node have **high** contour gradient

$$H(x) = \boxed{\text{mean}_i} H(N_i)$$ → lymph nodes have **positive** HU value; brown fat has **negative** HU value

$$S(x) = \boxed{\min_i} S(N_i)$$ → lymph nodes have **low** standard deviation

$$R(x) = \boxed{\max_i} R(N_i)$$ → lymph nodes have **high** contrast with their neighbourhood

$$L(x) = \boxed{\text{or}_i} L(N_i)$$ → lymph nodes are **ouside** the lungs convexhull

# Automatic lymph node tumor segmentation in PET/CT

## 4. CNN and component-tree fusion

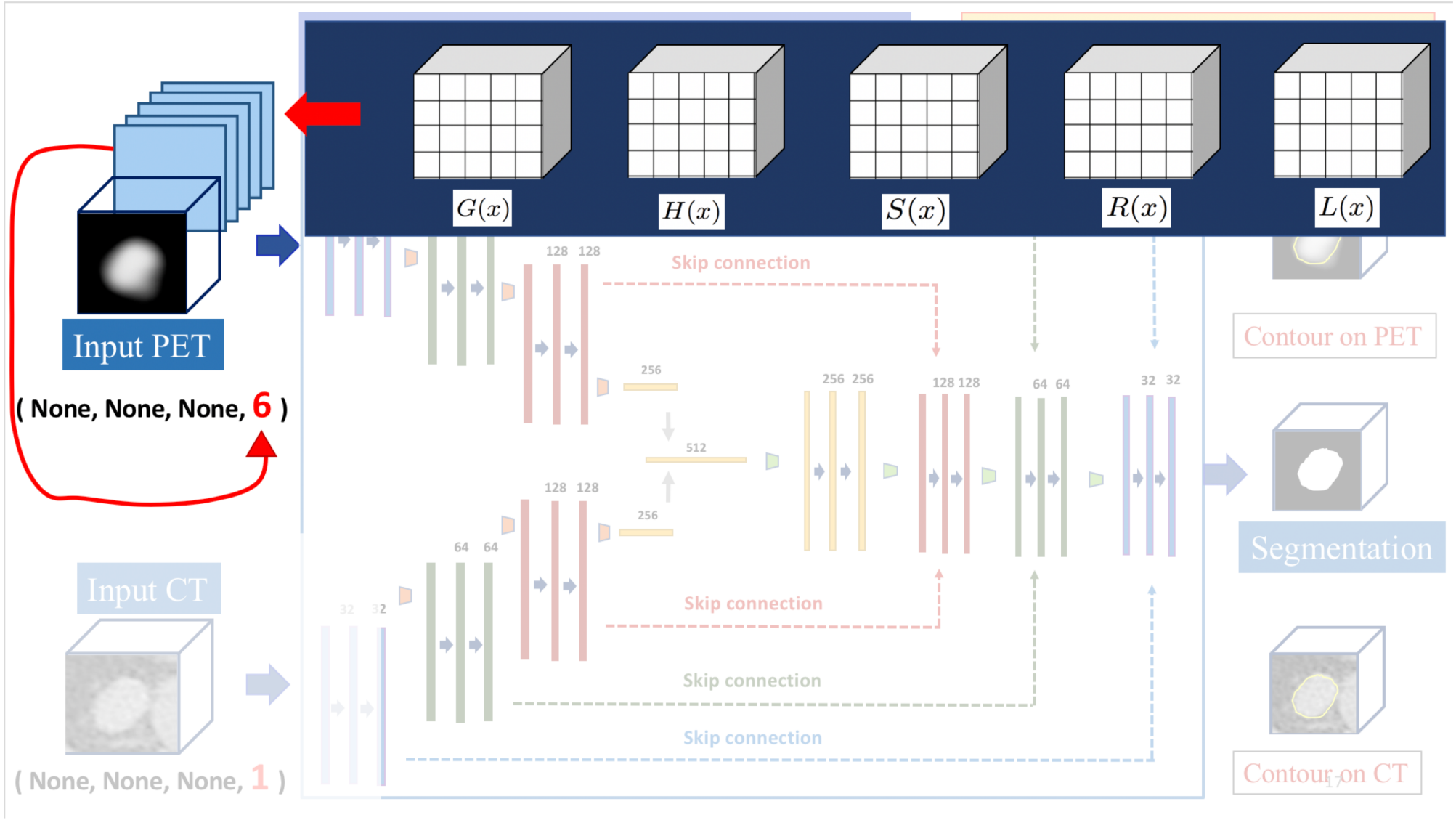

# 5. CNN

## 3D U-Net PET-CT for LN tumor segmentation (2 encoders + 1 decoder)

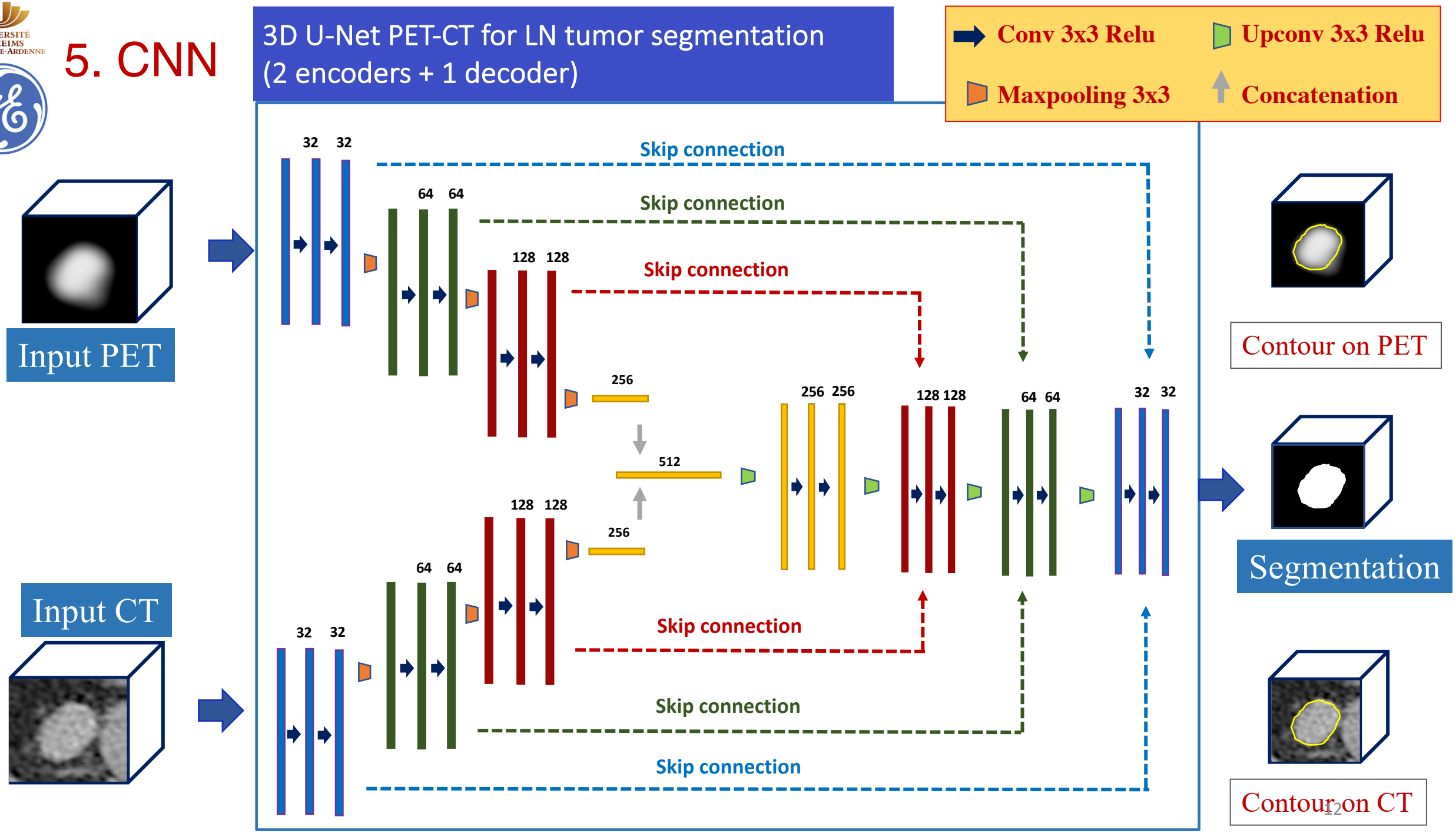

# Automatic lymph node tumor segmentation in PET/CT

## 6. Results

| | |
|---|---|
| **Training:** | 201 tumors (42 PET/CT exams) |
| **Validation:** | 56 tumors |
| **Patches for test:** | 63 tumors (10 PET/CT exams) |
| **Loss Function:** | 1 - Dice |
| **Iterations:** | 1000 |

| | |
|---|---|
| **Type of CNN:** | U-NET |
| **Number of layers:** | 3 |
| **Resolution** | $1.2mm^3$ |
| **3D Patch size:** | $80\ mm^3$ |

baseline → U-PET-CT → inputs {PET, CT}

proposed method → U-PET-CT-all → inputs {PET, CT, all feature maps}

U-PET → inputs {PET}

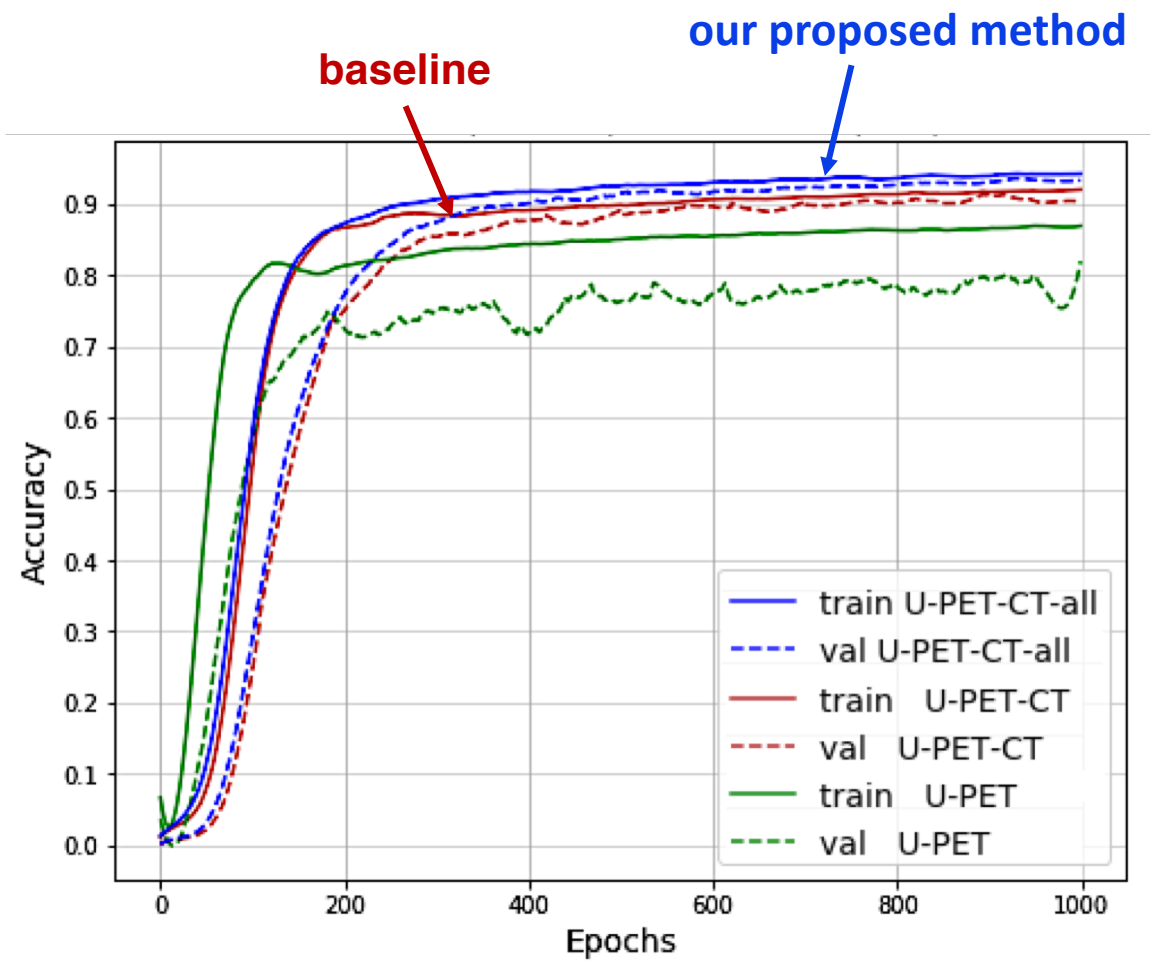

# Automatic lymph node tumor segmentation in PET/CT

## 6. Results

U-PET → inputs {PET}

U-PET-CT → inputs {PET, CT}

U-PET-CT-all → inputs {PET, CT, all feature maps}

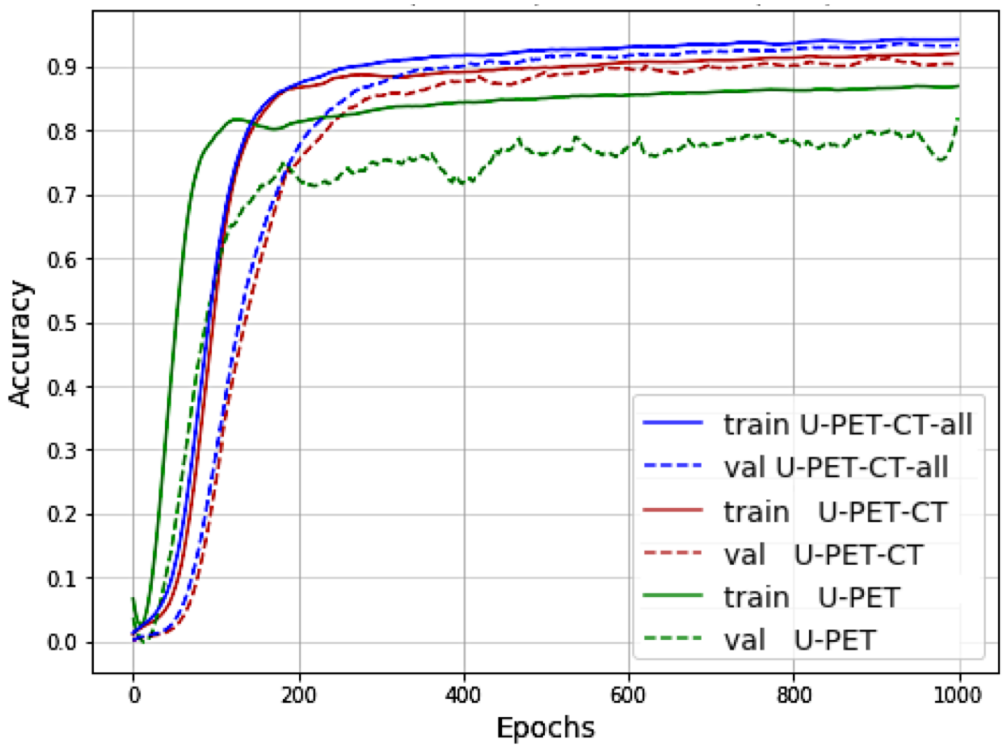


| 3D CNN Model | Voxel-based metrics (Segmentation) | | | Region-based metrics (Detection) | | |
|---|---|---|---|---|---|---|
| | DSC voxel | PPV voxel | SE voxel | DSC region | PPV region | SE region |
| 3D U-Net (PET) | **0.832703** +- 0.1327 | **0.827762** +- 0.1483 | **0.82478** +- 0.0868 | **0.798685** +- 0.1547 | **0.757925** +- 0.2206 | **0.890805** +- 0.0821 |
| 3D U-Net (PET-CT) | **0.865896** +- 0.08 | **0.844429** +- 0.1034 | **0.886527** +- 0.0465 | **0.871825** +- 0.1312 | **0.849864** +- 0.1893 | **0.926111** +- 0.0628 |
| 3D U-Net (PET-CT-all) | **0.867845** +- 0.1161 | **0.872781** +- 0.1425 | **0.896473** +- 0.0553 | **0.894624** +- 0.1431 | **0.851361** +- 0.1948 | **0.933135** +- 0.0756 |

baseline → 3D U-Net (PET-CT)

proposed method → 3D U-Net (PET-CT-all)

# Automatic lymph node tumor segmentation in PET/CT

## 6. Results

**Proposed method removes false positives coming from brown fat**

**Results shown on the PET/CT fusion images**

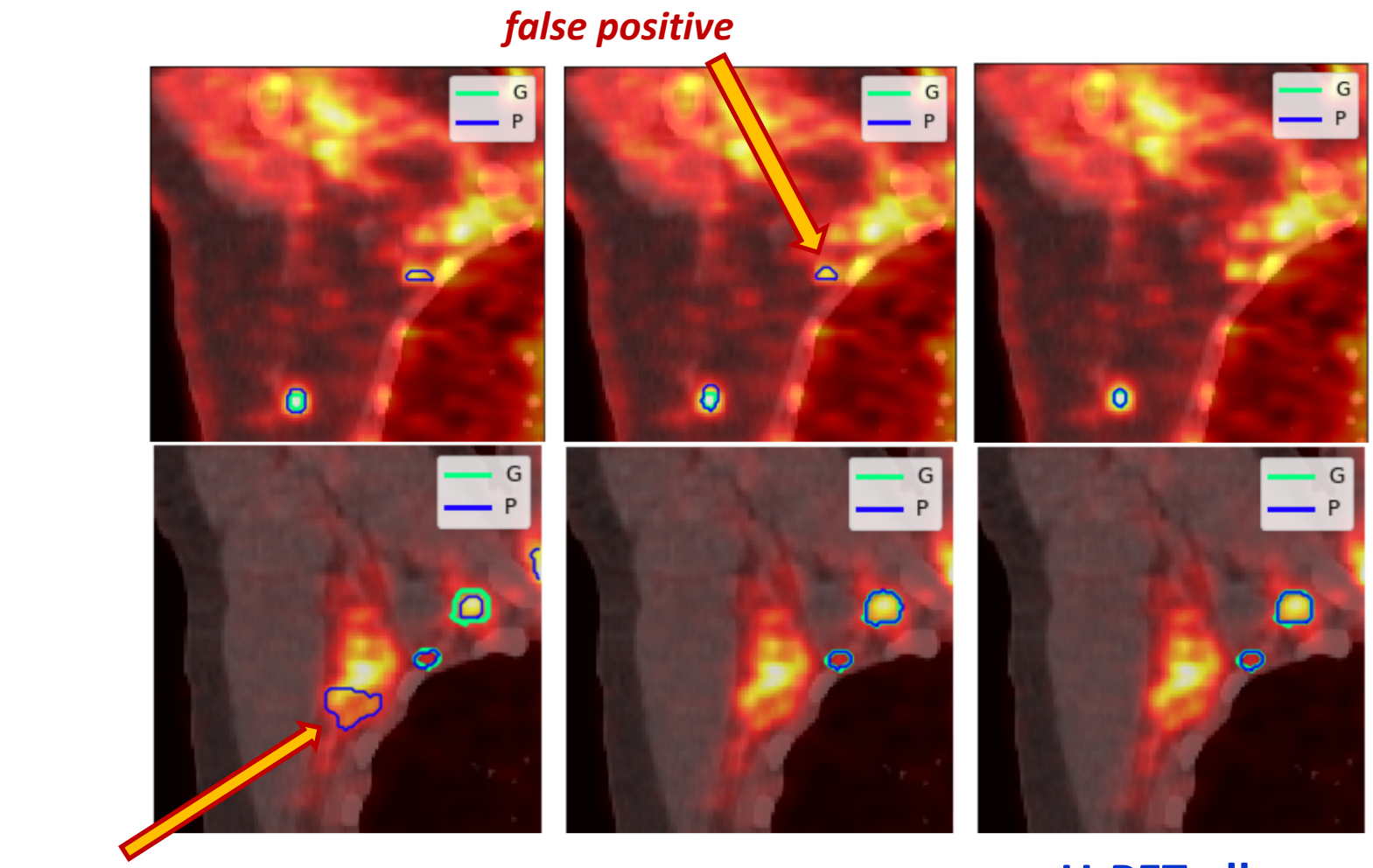


**U-PET** | **U-PET-CT** *(baseline)* | **U-PET-all** *(proposed method)*

# Automatic lymph node tumor segmentation in PET/CT

## 6. Results

**Proposed method separates visually connected tumors**

**Results shown on the PET/CT fusion images**

*false positive*

*false positive*

*joined contours*

*separated contours*

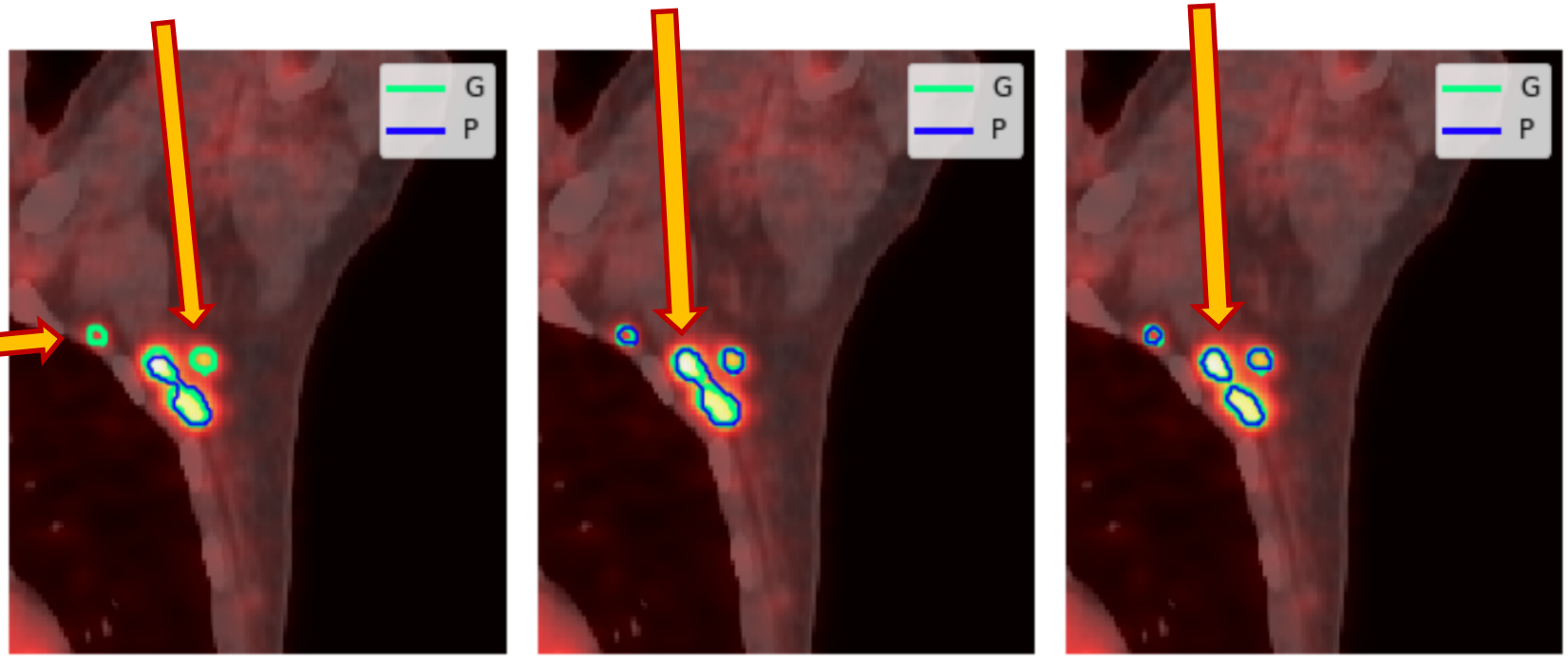


**U-PET**

**U-PET-CT**
***(baseline)***

**U-PET-all**
***(proposed method)***

# Thank you for your attention

mail: diana.lucia.farfan@gmail.com

page: linkedin.com/dianafarfan